



# Relapse of anterior open bites treated with orthodontic appliances with and without orofacial myofunctional therapy

JoAnn Smithpeter<sup>a</sup> and David Covell, Jr<sup>b</sup>

Portland, Ore

**Introduction:** Closure and long-term retention of anterior open bites are significant concerns for orthodontists and their patients. In this study, we investigated the efficacy of orofacial myofunctional therapy (OMT) for maintaining closure of open bites in conjunction with orthodontic treatment. **Methods:** The sample included 76 subjects with dental anterior open bites referred for OMT before, during, or after relapse of orthodontic treatment. The experimental cohort consisted of 27 subjects who received OMT and orthodontic treatment or retreatment. The control cohort comprised 49 subjects who had a history of orthodontic treatment with open-bite relapse. Overbite was evaluated by an OMT professional or orthodontist 2 months to 23 years after removal of the fixed appliances. Measurements were compared with *t* tests. **Results:** Overbite relapse means were 0.5 mm (range, 0.0-4.0 mm) in the experimental group and 3.4 mm (range, 1.0-7.0 mm) in the control group, a difference that was clinically and statistically significant ( $P < 0.0001$ ). **Conclusions:** This study demonstrated that OMT in conjunction with orthodontic treatment was highly effective in maintaining closure of anterior open bites compared with orthodontic treatment alone. (Am J Orthod Dentofacial Orthop 2010;137:605-14)

There is general agreement among orthodontists that patients with anterior open bites are challenging to treat, and relapse is common after treatment with orthodontics alone or combined with orthognathic surgery.<sup>1-21</sup> The orthodontic literature describes various methods for treatment and retention aimed at decreasing the risk of open-bite relapse, including functional and fixed appliances,<sup>9,11</sup> tongue spurs or cribs,<sup>12,20,22</sup> elastics,<sup>15,17</sup> wires,<sup>23</sup> molar intrusion,<sup>15</sup> orthognathic surgery,<sup>2,4</sup> extractions,<sup>3</sup> partial glossectomy,<sup>6</sup> and orofacial myofunctional therapy (OMT).<sup>24-41</sup> Investigators have cited tongue position or activity as reasons for difficulty in achieving long-term closure of anterior open bites.<sup>9,12,13,18-28</sup> With

this in mind, many authors have stated that OMT or other muscle training and habituation exercises might be useful; however, the benefits of OMT remain questionable to many.<sup>3,9,12,15,18,21,22,42-50</sup>

The reasons cited for lack of enthusiasm for OMT in orthodontic practices include (1) limited office space for providing therapy, (2) absence of OMT providers, (3) difficulty and amount of time required,<sup>51</sup> (4) inadequate training, (5) hope that function will follow form, (6) belief that there is insufficient scientific evidence to support OMT,<sup>18,50,52,53</sup> and (7) observations that not all OMT providers have the same expertise, so successful results are unpredictable.<sup>12,29</sup> It is clear that additional research needs to be published in the orthodontic literature to evaluate OMT for the treatment of anterior open bites. Table I lists 22 studies that have documented outcomes of anterior open-bite treatment and is divided into 3 sections. The first section shows the percentages of relapsed subjects in 11 comprehensive studies totaling 1416 subjects not using OMT. The second section represents 4 patients from case reports who received tongue training with orthodontic appliances and 5 who had orthodontic appliances only. These 9 patients were reported as having no relapse. The third section lists 4 studies that documented the amount of closure of open bites with OMT alone in 195 patients.

<sup>a</sup>Speech pathologist and certified orofacial myologist, private practice, Lake Oswego, Ore; adjunct faculty, Portland State University, Portland, Ore.

<sup>b</sup>Associate professor and chair, Department of Orthodontics, Oregon Health & Science University, Portland, Ore.

Partially funded by the Committee for Research on Orofacial Myology (John P. Howland, chairman), which ceased operation and donated its treasury to the Portland State University Foundation. Preliminary findings were presented at the Annual Convention of the International Association of Orofacial Myology, June 17, 2005, in Vancouver, British Columbia, Canada.

The authors report no commercial, proprietary, or financial interest in the products or companies described in this article.

Reprint requests to: JoAnn Smithpeter, 3931 SW South Shore Blvd, Lake Oswego, OR 97035; e-mail, [spchpthpc@comcast.net](mailto:spchpthpc@comcast.net).

Submitted, June 2007; revised and accepted, July 2008.

0889-5406/\$36.00

Copyright © 2010 by the American Association of Orthodontists.

doi:10.1016/j.ajodo.2008.07.016

**Table I.** Anterior open bite treatment and results

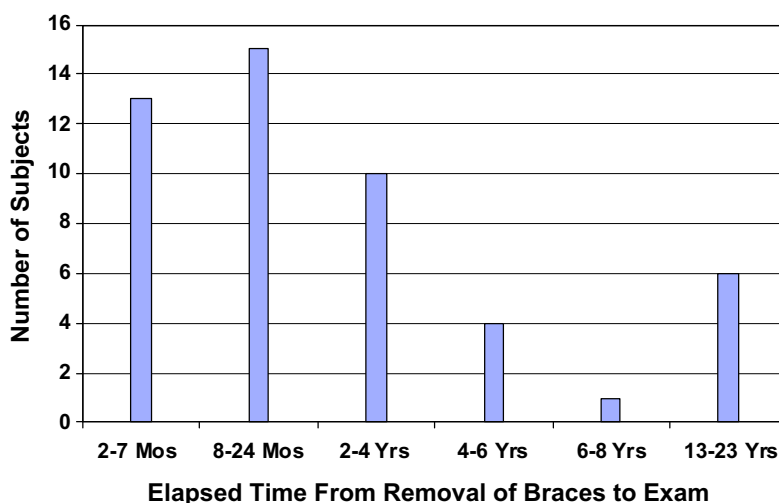
<i>Author</i>	<i>Method</i>	<i>Mean closure</i>	<i>Relapse</i>	<i>n</i>
Comprehensive studies, postorthodontic treatment				
Lopez-Gavito et al <sup>1</sup>	Appliances	35% relapsed 3 mm or more		41
Dennison et al <sup>2</sup>	Surgery	42.9% relapsed		66
Janson et al <sup>3</sup>	Non-extraction; fixed appliances	38.1% relapsed		21
Hoppenreijts and van der Linden <sup>4</sup>	Orthodontics and surgery	19% relapsed		?
Al Yami et al <sup>5</sup>	Appliances	33% relapsed		1016
Lo and Shapiro <sup>6</sup>	Surgery	25% relapsed; 0.7-1.0 mm cited as insignificant		40
Gile <sup>7</sup>	Appliances	35% relapsed more than 1 mm		100
Katsaros and Berg <sup>11</sup>	Appliances	25% relapsed; those who could advance mandible to achieve incisor occlusion were not considered relapsed		20
Zuroff <sup>18</sup>	Appliances	60% relapsed; maximum relapse was 2.4 mm		64
Kim et al <sup>23</sup>	Multiloop edgewise archwire	Insignificant relapses of 0.23 mm for growing and 0.35 mm for nongrowing subjects		55
Huang et al <sup>20</sup>	Cribs	17% relapsed		33
Case reports, postorthodontic treatment and muscle therapy				
Zimmerman <sup>37</sup>	OMT and appliances	0.0 mm		1
Justus <sup>22</sup>	Spurs	0.0 mm		3
Beane <sup>19</sup>	Appliances	0.0 mm		1
Efstratiadis <sup>59</sup>	Appliances	0.0 mm		1
Lindsey and English <sup>15</sup>	Appliances and muscle therapy	0.0 mm		1
Lee <sup>28</sup>	Appliances and muscle therapy	0.0 mm		1
Alexander <sup>31</sup>	Appliances, muscle therapy, and extractions	0.0 mm		1
OMT				
Haruki et al <sup>24</sup>	OMT only	5.0 and 2.5 mm		2
Benkert <sup>33</sup>	OMT only	1.5 mm		90
Daglio et al <sup>34</sup>	OMT only	5.5 mm		28
Daglio et al <sup>35</sup>	OMT only	2.1 mm		75

Characterizations of open bites have varied. Chase<sup>26</sup> described open bite as a condition characterized by space discrepancies between the occlusal and incisal surfaces of the maxillary and mandibular teeth when the mandible is brought into habitual or centric occlusion. Ferguson<sup>53</sup> stated that, in the United Kingdom, an anterior open bite is described as the absence of vertical incisor overlap between the maxillary and mandibular incisors, whereas an incomplete overbite has vertical overlap, but the mandibular incisors fail to make contact with either their antagonists or the palate. He also noted that, in the United States, both conditions have been called anterior open bite, but, with a true anterior open bite, it is impossible to achieve incisor contact, whereas this can sometimes be accomplished if the mandible is protruded in patients with incomplete overbites. In our study, open bites were defined as the mandibular incisors failing to make contact with their antagonist teeth or the palate when observed with the posterior teeth in maximum intercuspation and no contact of incisors with excursive movements.

In this investigation, we compared subjects who were treated with orthodontics alone vs those treated with orthodontics combined with OMT; we used retrospective data from the practice of an orofacial myofunctional therapist (J.S.). The purpose was to evaluate whether completion of an OMT program before removal of the orthodontic appliances decreases the risk of relapse of closed anterior open bites.

## MATERIAL AND METHODS

All subjects were referred by orthodontists to an OMT private practice because of dental anterior open bites and Angle Class I or Class II malocclusion. Open bite was measured to the nearest whole number as the vertical discrepancy between incisal edges of the mandibular central incisors and the lingual surface of the maxillary incisors or palate. No subject could contact the incisors by protruding the mandible, thus fitting the criterion of a true anterior open bite according to Ferguson.<sup>53</sup> The experimental group of patients



**Fig 1.** Time between removal of appliances and the OMT examination of the 49 control subjects (mean,  $4 \pm 6$  y).

having orthodontic treatment and OMT was compared with the control subjects, who had received only orthodontic treatment.

The control cohort consisted of 49 patients referred by 28 orthodontic practices for an OMT examination after orthodontic relapse. They included 15 male and 34 female subjects with a mean age of 17 years 8 months (SD, 7 years 9 months; range, 10-41 years) at the OMT examination. At debanding, 44 (90%) of the control subjects were reported by their orthodontists to have closed open bites; 3 subjects remained open from 0.5 to 2.0 mm (mean, 1.2 mm), and 2 subjects were not closed, but the amount of open bite at the time of discharge had not been recorded. Eighty-four percent of the subjects or their families noticed their bites opening within 2 years after debanding, although only 58% were professionally measured within 2 years. The time between active orthodontic treatment and the OMT examination ranged from 2 months to 23 years (mean, 3 years 11 months; SD, 5 years 11 months; Fig 1). The distribution of the amounts of relapse in control subjects was relatively symmetric compared with the experimental subjects (Fig 2). Forty-five of the 49 control subjects were not seen again in the OMT practice, but 4 patients chose to receive OMT and orthodontic retreatment and also became part of the experimental cohort.

The experimental group comprised 27 subjects who had been referred for OMT from 20 orthodontic practices, either before or during orthodontic treatment. They included 5 male and 22 female subjects with a mean age of 14 years 1 month (SD, 6 years 5 months; range, 8-38 years) when OMT was completed between

1981 and 2003. Four subjects had relapsed after active orthodontic treatment (from the control group above), and 23 subjects had no previous history of fixed orthodontic treatment. The patients were treated by orofacial myologists in 1 practice, which used a standardized approach as instructed by the first author (J.S.). They were reevaluated 5 months to 20 years (mean, 6 years 2 months; SD, 4 years 2 months) after orthodontic treatment (Fig 3). Their ages at the follow-up for the experimental group were 14 to 39 years (mean, 20 years 3 months; SD, 6 years 5 months); 96% of the patients were measured a minimum of 2 years after their last OMT visit. Overbite measurements were made by either an OMT therapist or orthodontist.

All initial and final examinations included a review of medical and dental histories, measurement of the amount of open bite, obtaining frontal intraoral photographs, and documentation of oral physiologic characteristics including habitual lip posture (open or closed), swallow patterns of the tongue (protruded or palatal), tongue rest posture (low forward or palatal), oral habits (digit sucking, lip licking or biting, or none), and speech articulation errors. Recitation of the alphabet and conversational speech were analyzed for accuracy of tongue and lip movements and sound production. Each item in the evaluations had a numeric value of 0 to 4; the sum categorized the subjects according to mild, moderate, severe, or profound dysfunction. For the experimental group, the OMT treatment regimen involved selectively prescribing exercises (from 49 exercise options) for normalization of orofacial muscles for rest, swallowing, eating, drinking, and speaking.

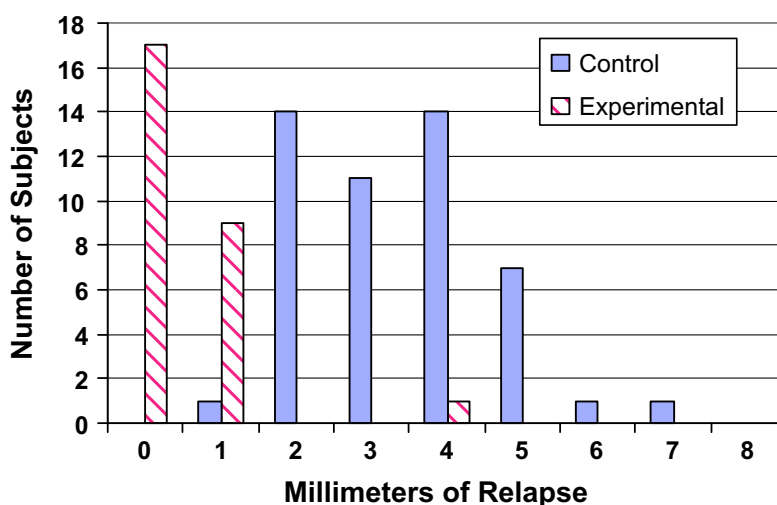


Fig 2. Comparison of the amounts of relapse in the control subjects vs the experimental subjects.

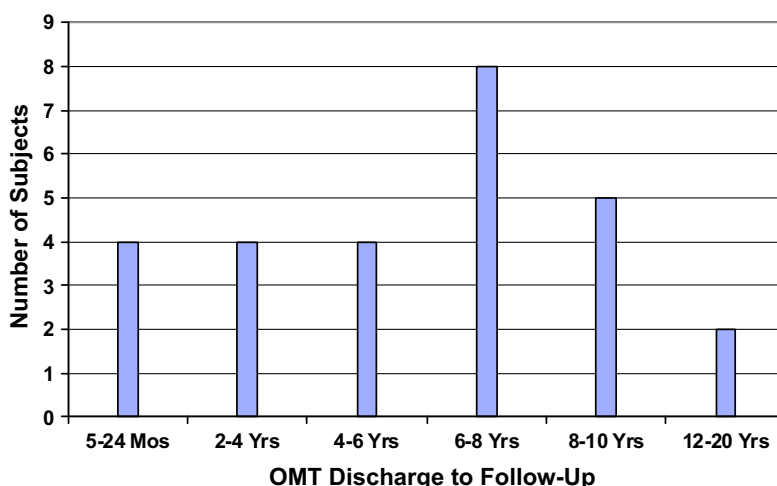


Fig 3. Time between OMT discharge and follow-up of the 27 experimental subjects (mean,  $6 \pm 4$  y).

Exercises, similar to the remedial program of Weiss and van Houten,<sup>41</sup> were printed and videotaped for home practice. The number of OMT exercises and sessions for each patient was determined by the severity of speech errors, oral habits, medical conditions, and the patient's motivation and response to the exercises (range, 1-32 sessions; mean,  $14 \pm 8$ ). At each visit, the orofacial myofunctional therapist assessed patient compliance and motivation. At the final OMT session, the original examination was readministered.

Relapse amounts were quantified clinically and the means compared between groups. To analyze whether there was any systematic bias between the 2 profes-

sionals, measurements made by orofacial myofunctional therapists vs orthodontists were compared. Overbite measurements of the experimental subjects were compared with their original measurements and with those of the control group. In the experimental cohort, differences in open-bite reduction of subjects who had not previously received orthodontic treatment were compared with subjects who had orthodontic retreatment. Based on the model of Kim et al,<sup>23</sup> suggesting that age might be a factor, subjects who were younger than 16 years after OMT were compared with older subjects. Differences in open-bite reduction and relapse were also compared between the sexes. The influence

**Table II.** Relapse differences

	Experimental group	Control group
Subjects (n)	27	49
Relapse range (mm)	0-4	1-7
Relapse mean (mm)	$0.48 \pm 0.8$	$3.38 \pm 1.3$
Standard deviation	0.8	1.3

Statistical comparison of the means confirmed a significant difference ( $P = 0.0000$ ).

of speech errors corrected vs not corrected was investigated to determine the effect on relapse. Correlations were made between the number of OMT sessions and initial open bite, oral habits, speech errors, and relapse.

For comparison of open-bite reduction and relapse,  $t$  tests were used, with the level of significance set at  $P < 0.05$ . Analysis of covariance was used for comparing the times between removal of the orthodontic appliances and the OMT examination in the control cohort, and between completion of the OMT and the follow-up in the experimental cohort. Linear regression analysis and correlation coefficients were used to identify characteristics that related to relapse in the control cohort and the amount of open-bite reduction and relapse in the experimental cohort.

## RESULTS

Comparison of measurements made by orofacial myofunctional therapists vs orthodontists at the follow-up showed the 2 did not differ statistically. The relapse differences between the experimental cohort (treated with orthodontics and OMT) and control cohort (treated with orthodontics alone) as shown by the  $t$  tests were highly statistically significant ( $P < 0.0001$ ; Table II). The distribution of relapse of the control subjects was relatively symmetric (Fig 2; range, 1-7 mm; mean,  $3.4 \pm 1.3$  mm). In the experimental group (Fig 2), 17 of the 27 subjects (63%) had no measureable relapse; 9 had a 1-mm relapse, and 1 had a 4-mm relapse. Thus, relapse of the experimental subjects was small. Overall, the experimental group showed  $0.48 \pm 0.8$  mm of open-bite relapse (Table II). The amounts of reduction in open bite were 1 to 8 mm (mean,  $3.6 \pm 2.0$  mm), and 63% of the experimental subjects had a 100% reduction in open bite (Fig 4).

In the experimental cohort, the mean reduction in open bite did not differ significantly between the treated and retreated subjects ( $P = 0.33$ ). Subjects younger than 16 years of age at OMT completion had significantly greater mean reductions of open bite than did those older than 16 ( $P < 0.05$ ), but the younger subjects also had greater open bites initially (mean, 4.65 vs 2.71

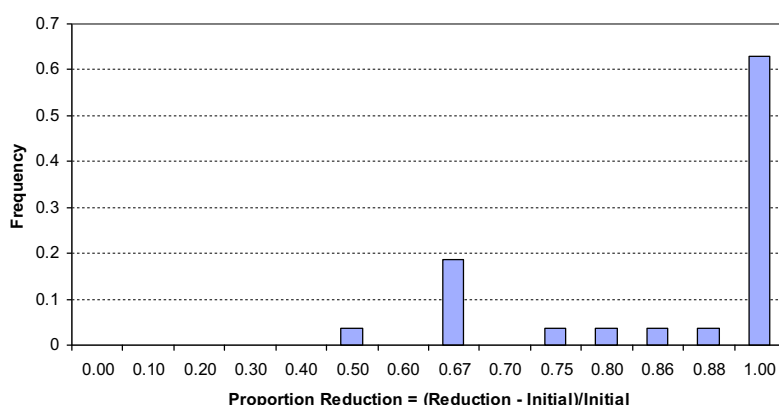
mm). Sex was not significantly associated with the amount of open-bite reduction. The correction of speech errors was not significantly associated with the amount of open-bite reduction ( $P = 0.33$ ) or relapse ( $P = 0.16$ ). The number of OMT sessions was associated with the severity of the orofacial myofunctional disorder, motivation, and compliance, but was not related to the stability of the overbite. There were no correlations between number of sessions, initial open bite, number of oral habits, number of speech errors, or amount of relapse. However, speech errors significantly decreased as the number of sessions increased ( $P < 0.01$ ).

In the control group, the mean time between active orthodontic treatment and the OMT examination was 3 years 11 months (Fig 1). In the experimental group, the mean time between completion of OMT and the follow-up OMT examination was 6 years 2 months (Fig 3). Time between OMT completion and follow-up in the experimental group was significantly longer than the time between active orthodontic treatment and the OMT examination in the control group ( $P < 0.05$ ). The initial measurements of open bite in the experimental group ranged from 1.0 to 8.0 mm (mean,  $4.1 \pm 2.1$  mm). The amount of open-bite reduction at follow-up ranged from 1.0 to 7.0 mm (mean,  $3.6 \pm 2.0$  mm). There was a high correlation between the amounts of initial open bite and open-bite reduction at follow-up ( $r = 0.92$ ;  $P < 0.001$ ).

In the control group, 74% of the subjects had oral habits, whereas at the final evaluation of the experimental subjects, the prevalence of oral habits was reduced from 55% to 0%. For speech errors, 82% of the control group retained their speech errors, but these in the experimental group were reduced from 90% to 26% of the subjects. Typical speech sounds misarticulated by both groups were *l*, *s*, *z*, *t*, *d*, *n*, *sh*, *ch*, and *j*. Tongue rest posture and swallow patterns were normal at the final evaluations for all experimental subjects.

## DISCUSSION

The results of this study show a clear difference between the outcomes of subjects with anterior open bites when treated with orthodontics alone compared with those treated with orthodontics and OMT. A key finding was that relapse in the experimental cohort treated with orthodontics and OMT ( $0.48 \pm 0.8$  mm) was significantly less than that in the control cohorts treated with orthodontics alone ( $3.38 \pm 1.3$  mm;  $P < 0.0001$ ; Table II). In addition to the 23 subjects who received OMT before or during orthodontic treatment, overbites remained stable in the 4 subjects who had previous



**Fig 4.** Proportion of the experimental cohort showing various amounts of reduction in open bite.

unsuccessful orthodontic treatment and then completed OMT and orthodontic retreatment.

In contrast with the findings of Kim et al,<sup>23</sup> who found no significant difference in relapse of subjects older vs younger than 16 years of age, our study demonstrated that, in older subjects, the reduction of open bite was less, and overbite stability was greater than in younger subjects. Because in this study the mean initial open bite was greater in the younger subjects, the amount of reduction was more likely to represent a difference in the subjects' initial presentation rather than an age-related difference in response to OMT and orthodontic treatment. Katsaros and Berg<sup>11</sup> suggested that relapse could be less in older subjects because there is less risk of unfavorable growth after treatment. Some dentists have treated pediatric patients successfully with the aid of OMT,<sup>24,29,34,35</sup> and they reported successful outcomes with children under the age of 10 years. Others suggested waiting until patients are 10 years of age or older.<sup>50</sup> According to Klocke,<sup>16</sup> spontaneous closure of open bites generally occurs until age 12.

Consistent with our investigation, other studies on open bites have had samples with more females than males,<sup>7,11,33,35</sup> but sex was not found to correlate with open-bite relapse.<sup>33,46</sup> It is unknown why more female subjects were involved, but it might be related to bias in treatment-seeking behavior, since women might be more interested in improving esthetics and function.

At the initial examinations by the orofacial myofunctional therapist, the magnitudes of the open bites were similar for the control (range, 1-7 mm; mean, 3.4 mm) and experimental subjects (range, 1-8 mm; mean, 4.2 mm). Analyses of the documented physiologic characteristics showed other findings common to both cohorts, including low, forward tongue rest posture, and tongue thrust swallow. These findings are sim-

ilar to the conclusion of Gile<sup>7</sup> that "presence of a tongue habit is related to anterior open-bite." In our study, oral habits (nail biting, thumb sucking, lip biting, lip licking) were more prevalent in the control than the experimental group; this leads to the speculation that oral habits can perpetuate forward tongue rest postures and tongue thrust swallows. Surprisingly, speech errors were more prevalent in the experimental group initially than in the control group. Neither correction nor retention of speech errors significantly influenced open-bite reduction or relapse, even though speech errors decreased after the OMT. The decreases in speech errors and oral habits in the experimental cohort might be attributed to changing the anterior tongue rest posture from low forward to alveolar or palatal. Incorrect articulation of lingual-alveolar speech sounds (*t*, *d*, *n*, and *l*) is typical in children with an abnormal tongue rest position. Hanson and Mason<sup>54</sup> proposed that, with affected patients, it is easier to leave the tongue against the front teeth, where it rests, than to lift it and move it posteriorly for the accurate production of lingual-alveolar speech sounds. With the tongue in a more normal position at rest, it is easier to articulate all speech sounds.

The wide range of OMT sessions (1-32; mean,  $14 \pm 8$ ) was due to variations in the severity of oromotor issues, medical conditions, educational level, compliance, schedules, and motivation. No variables documented were statistically significant in determining the number of sessions. However, subjects who attended the most sessions had the greatest amount of speech improvement. Other researchers have reported on the number of sessions or the duration of treatment. The patients of Daglio et al<sup>34</sup> received an average of 24 half-hour sessions of OMT compared with the average of 14 half-hour sessions in our sample. The duration of OMT for the 2 patients described by Haruki et al<sup>24</sup> was

PRETREATMENT MYOFUNCTIONAL SCREENING				
NAME: (Last) (First)	SEX: M F	AGE: Yrs __ Mos __	BD: __/__/__	DATE: __/__/__
Observe pt. in upright position	NORMAL	ABNORMAL	COMMENTS	
<b>BREATHING:</b>				
Lips Open				
Lips Closed				
Ability to breathe through nose				
<b>OCCCLUSION:</b>				
Openbite				
Overjet				
<b>SPEECH:</b>				
	a b c d e f g h i j k l m n o p q r s t u v w x y z, sh, th			
p b m – bilabial closure				
t d n l – tongue tip to alveolar ridge				
s z g h j sh – no tongue showing				
<b>TONGUE REST POSTURE:</b>				
Up				
Down				
Forward				
<b>SWALLOW:</b>				
1- Observe automatic saliva swallows.				
Grimace				
No facial movement				
2- Observe drinking water from clear cup.				
Tongue protrudes				
No tongue protrusion				
3-Observe eating a cracker				
Messy				
Tidy				
<b>SUCKING HABITS:</b>				
Thumb				
Finger(s)				
Other				
(Count the check marks) TOTALS				

**RECOMMENDATIONS:**

**REFERRALS TO:** \_\_\_\_\_

**Fig 5.** OMT protocol.

11 months, with 8 sessions for 1 child and 11 sessions for the other. They reported that eliminating thumb-sucking accomplished the closure, but long-term stability was not reported. Huang et al<sup>20</sup> reported long-term stability in nongrowing subjects after they used cribs for a year. Some studies show open-bite closure by eliminating thumb and tongue habits without an appliance,<sup>24,33-35,37-40</sup> but Cooper<sup>32</sup> found little difference between open-bite patients treated with OMT vs fixed crib appliances. He studied 3 groups—OMT, crib, and control—and found that, after 6 months of treatment, both the OMT and crib groups had proper swallow patterns on command, whereas the maturational guidance (control) group did not. Whether proper swallows had become habitual or were only demonstrated on command was not stated. Cooper<sup>32</sup> found that, after treatment with OMT or a tongue crib, open bites did not relapse.

The intervals between end of treatment and follow-up were significantly longer in the experimental group

than in the control group; thus, the experimental group had a longer time in which to relapse than did the controls (Figs 1 and 3). The findings show that, on average, the control subjects relapsed sooner than the experimental subjects, if they relapsed at all. Although it is often thought that in many situations function will follow form, results from our control group showed exceptions to this concept. The OMT examination showed that the 49 control subjects continued their abnormal functions with low, forward tongue rest posture and tongue thrust swallow even though their bites had at 1 time been closed or nearly closed. Findings in the literature vary regarding the stability of open-bite closure. Yashiro and Takada<sup>13</sup> postulated that function followed form in an adult who could swallow without thrusting the tongue. They reported that, after orthodontic treatment and 2 years of retention in which tight intercuspation and lip seal were obtained, it was possible to achieve negative intraoral pressure,



a necessity for normal swallow. Olive and Basford<sup>14</sup> observed relapse in overbite within 3 months to 2 years after orthodontic treatment, irrespective of the type of retention. Similarly, we documented changes in overbite as early as 2 months after active orthodontic treatment. Al Yami et al<sup>5</sup> found that 67% of the achieved orthodontic treatment result was maintained 10 years postretention, and about half of the total relapse (measured with the peer assessment rating index) had occurred in the first 2 years after retention. Janson et al<sup>3</sup> evaluated stability of open-bite correction for a mean of 5 years after nonextraction orthodontic treatment in the permanent dentition and found that 61.9% of the subjects had clinically stable open-bite correction.

In this study, no open bite was used for defining relapse, and 63% of the experimental subjects showed stability, whereas other investigators considered 1 to 3 mm of open-bite relapse insignificant (Table I).<sup>1,6,7,11</sup> Because 26 of our 27 experimental subjects had 1 mm or less of open bite at follow-up, the threshold of 1 mm would show that 96% remained stable. This amount of relapse is in striking contrast to studies listed in the first section of Table I, with relapse reported in 12% to 60% of subjects after orthodontic treatment without OMT. With the combined treatment approach, emphasis on normalization of oral functions most likely contributed to the stability. The potential benefit of combined OMT and orthodontic treatment as opposed to OMT alone is suggested by comparing our results with those of studies in the last section of Table I. In those studies, the mean amount of open-bite closure (reduction) for 195 subjects receiving OMT without orthodontic treatment was 2.3 mm compared with 3.6 mm in our study.

Details of the orthodontic treatment mechanics were not documented in this study and were no doubt variable because of the many orthodontic practices involved. The only orthodontic treatment approach reported in the literature review that showed minimal relapse was the multiloop edgewise technique.<sup>23</sup> According to Kim et al,<sup>23</sup> only 1 adult of the 55 growing and non-growing patients treated with this method had abnormal tongue function and posture at the start of treatment, and had a "small amount of relapse." In addition to biomechanically repositioning the anterior teeth with orthodontic treatment, overbite stability in our study was probably influenced by elimination of speech errors and oral habits in addition to normalizing tongue rest and swallow patterns. Gile,<sup>7</sup> after studying 100 anterior open-bite patients, determined that, since the relapse group had a higher incidence of tongue problems than did the nonrelapse group, dental practitioners should tell patients before orthodontic treatment that open-bite closure is uncertain at best if there are tongue

habits. Carvalho et al<sup>36</sup> also determined that an accurate assessment of particular parameters before orthodontic treatment might aid in the completion and stability of orthodontic patients. Dehan and Lelong<sup>46</sup> published a straightforward screening chart to evaluate the presence and severity of tongue thrust. The original brief protocol (Fig 5) can be used quickly as a pretreatment screening tool by anyone in a dental office to determine the advisability of referring to an ear, nose, and throat physician to assess nasal patency for breathing in patients with open-mouth or lips-apart. Referral to an OMT therapist is also recommended for a thorough assessment of oral habits and oral-motor issues, to determine whether treatment is indicated.

The mechanism of OMT was suggested by Svensson et al.<sup>55</sup> He demonstrated plasticity in corticomotor control of the tongue musculature induced by tongue-task training. This plasticity of the central nervous system might explain why patients can learn and habituate new tongue, lip, and jaw patterns with OMT. Interestingly, in studies on the duration and effectiveness of orthodontic treatment, when there was no explanation for about half of treatment overruns or poor outcomes, tongue posture and tongue thrust were not listed among the variables examined.<sup>55,56</sup> If tongue habits had been examined, there might have been better insight into the unexplained outcomes. Tongue rest posture could be more important than swallow patterns in dental open-bite patients.<sup>50</sup> Daglio et al<sup>35</sup> stated that the success of orthodontic treatment and the stability of its results are jeopardized by failure to identify dysfunctions and habits of tongue and lips. The results of this study and others show the benefit of collaboration between orthodontists and myofunctional therapists.<sup>24,25,29,41,57,58</sup>

This treatment outcome study provides evidence that was lacking in the scientific literature.<sup>18,50,52,53,56</sup> The findings indicate that patients with anterior open bites accompanied by oral habits, speech errors, tongue thrust, and low forward tongue rest posture have a major risk for relapse after orthodontic treatment if these characteristics are not altered before removal of the orthodontic appliances. Nevertheless, this study had some limitations because of the retrospective sample and the data collection. One limitation was that, because it was a longitudinal study, some potential experimental subjects had moved away and were unavailable for follow-up, thus reducing the sample size. Another limitation relates to an inherent bias, with the cohorts collected from an OMT office after referral by orthodontists for consultations and treatment pertaining to anterior open bites. Thus, the 2 cohorts give no insight into the characteristics and treatment outcomes of patients with anterior open bites that were treated



successfully with orthodontics alone. The stability in the experimental cohort was good for nearly all subjects and for a higher percentage of subjects than described in previous studies of open-bite treatment by orthodontics alone.<sup>1,3,5,7,11,18</sup> However, the outcome relative to orthodontic treatment alone could not be determined directly except for the 4 subjects who were retreated successfully, and this sample size was minimal.

For future studies, protocols could be designed to compare various orthodontic treatment and retention protocols on consecutively treated open-bite patients with forward tongue posture or forward swallow. In addition, a randomized prospective clinical trial could assign subjects to OMT or no OMT along with orthodontic treatment. Because most open-bite relapse occurs during the first 5 years, all follow-ups could be done at that time.<sup>3,5,6,14,23,28,38,41,57</sup> The results of this report and many others strongly suggest that, for any study aiming to evaluate the efficacy of open-bite treatment, methodical documentation of oral habits and function (Fig 5) should be made in addition to evaluating more traditional orthodontic diagnostic records. This could discriminate between patients who would benefit most from combined OMT and orthodontic appliances vs those who would have a good prognosis with orthodontic appliances alone.

## CONCLUSIONS

1. OMT with orthodontic treatment was efficacious in closing and maintaining closure of dental open bites in Angle Class I and Class II malocclusions, and it dramatically reduced the relapse of open bites in patients who had forward tongue posture and tongue thrust. Correcting low forward tongue posture and tongue thrust swallows minimized the risk of orthodontic relapse.
2. Speech errors and oral habits were associated with relapse but were often correctable with OMT. Retention of speech errors did not necessarily preclude correction of tongue rest posture and swallows.
3. In addition to dental anterior open bites, common denominators in both cohorts at the initial OMT examination were forward tongue rest posture and tongue thrust swallows, and the only common denominators in the stable experimental subjects were palatal tongue rest posture and swallow.

We thank the International Association of Orofacial Myology for its financial contributions and encouragement. The monies were paid to students Amy Davis,

who assisted in compiling the data; and Tang Tang and Toan Pham, who analyzed the data. We also thank Doug Neeley, director of the Statistical Consulting Laboratory at Portland State University, for supervising the data analysis and writing the statistical report.

## REFERENCES

1. Lopez-Gavito GW, Little TR, Joondeph DR. Anterior open-bite malocclusion: a longitudinal 10-year postretention evaluation of orthodontically treated patients. *Am J Orthod* 1985;87:175-86.
2. Dennison TF, Kokich VG, Shapiro PA. Stability of maxillary surgery in openbite versus nonopenbite malocclusions. *Angle Orthod* 1989;59:5-10.
3. Janson G, Valarelli FP, Henriques JFC, de Freitas MR, Cançado RH. Stability of anterior open bite nonextraction treatment in the permanent dentition. *Am J Orthod Dentofacial Orthop* 2003;124:265-76.
4. Hoppenreijts TJ, van der Linden FP. Afdeling mond-en kaakchirurgie, Academisch Ziekenhuis te Nijmegen. *Ned Tijdschr Tandheelkd* 1992;99:444-9.
5. Al Yami EA, Kuijpers-Jagtman AM, van't Hof MA. Stability of orthodontic treatment outcome: follow-up until 10 years postretention. *Am J Orthod Dentofacial Orthop* 1999;115:300-4.
6. Lo FM, Shapiro PA. Effect of presurgical incisor extrusion on stability of anterior open bite malocclusion treated with orthognathic surgery. *Int J Adult Orthod Orthognath Surg* 1998;13:23-34.
7. Gile RA. A longitudinal cephalometric evaluation of orthodontically treated anterior openbites [thesis]. Seattle: University of Washington; 1972.
8. BeGole EA, Sadowsky C. Methodologies for evaluating long-term stability of dental relationships after orthodontic treatment. *Semin Orthod* 1999;5:142-50.
9. Burford D, Noar JH. The causes, diagnosis and treatment of anterior open bite. *Dent Update* 2003;30:235-41.
10. Sarver DM. Commentary: Huang GJ, Justus R, Kennedy DB, Kokich VG. Stability of anterior openbite treated with crib therapy. *Angle Orthod* 1990;60:25.
11. Katsaros C, Berg R. Anterior open bite malocclusion: a follow-up study of orthodontic treatment effects. *Eur J Orthod* 1993;15:273-80.
12. Justus R. Treatment of anterior open bite: a cephalometric and clinical study. *ADM* 1976;33:17-40.
13. Yashiro K, Takada K. Tongue muscle activity after orthodontic treatment of anterior open bite: a case report. *Am J Orthod Dentofacial Orthop* 1999;115:660-6.
14. Olive RJ, Basford KE. A longitudinal index study of orthodontic stability and relapse. *Aust Orthod J* 2003;19:47-55.
15. Lindsey CA, English JD. Orthodontic treatment and masticatory muscle exercises to correct a Class I open bite in an adult patient. *Am J Orthod Dentofacial Orthop* 2003;124:91-8.
16. Klocke A, Nanda RS, Bärbel KN. Anterior open bite in the deciduous dentition: longitudinal follow-up and craniofacial growth considerations. *Am J Orthod Dentofacial Orthop* 2002;122:353-8.
17. Sheridan JJ, McFall J, Layfield LL. Force-amplified retention for corrected anterior open bites. *J Clin Orthod* 1997;31:817-9.
18. Zuroff J. Orthodontic treatment of anterior open-bite malocclusion: stability ten years post-retention. Cited by Shapiro PA. Stability of open bite treatment. *Am J Orthod Dentofacial Orthop* 2002;121:566-8.
19. Beane RA Jr. Nonsurgical management of the anterior open bite: a review of the options. *Semin Orthod* 1999;5:275-83.

20. Huang GJ, Justus R, Kennedy DB, Kokich VG. Stability of anterior openbite treated with crib therapy. *Angle Orthod* 1990;60:17-24.
21. Gershater MM. The proper perspective of open bite. *Angle Orthod* 1972;42:263-72.
22. Justus R. Correction of anterior open bite with spurs: long-term stability. *World J Orthod* 2001;2:219-31.
23. Kim YH, Han UK, Lim DD, Serrao MLP. Stability of anterior openbite correction with multiloop edgewise archwire therapy: a cephalometric follow-up study. *Am J Orthod Dentofacial Orthop* 2000;118:43-54.
24. Haruki T, Kishkik K, Zimmerman J. The importance of orofacial myofunctional therapy in pediatric dentistry. *ASDC J Dent Child* 1999;66:103-9.
25. Cottingham LL. Myofunctional therapy. *Orthodontics-tongue thrusting-speech therapy*. *Am J Orthod* 1976;69:679-87.
26. Chase WR. Imperative early treatment of anterior open bite. *Gen Dent* 1993;41:307-9.
27. Champagne M. The anterior open bite problem (infraclusion). *J Gen Orthod* 1995;6:5-10.
28. Lee BW. Treatment of anterior open bite with tongue thrust and associated temporo-mandibular joint symptoms. *Aust Orthod J* 1993;12:246-9.
29. Ohno T, Yogosawa F, Nakamura K. An approach to openbite cases with tongue thrusting habits with reference to habit appliances and myofunctional therapy as viewed from an orthodontic standpoint: part one. *Int J Orofacial Myology* 1981;7:5-10.
30. Takahashi S, Kuribayashi G, Ono T, Ishiwata Y, Kuroda T. Modulation of masticatory muscle activity by tongue position. *Angle Orthod* 2005;75:35-9.
31. Alexander CD. Open bite, dental alveolar protrusion, Class I malocclusion: a successful treatment result. *Am J Orthod Dentofacial Orthop* 1999;116:494-500.
32. Cooper JS. A comparison of myofunctional therapy and crib appliance effects with a maturational guidance control group. *Am J Orthod* 1977;72:333-4.
33. Benkert KK. The effectiveness of orofacial myofunctional therapy in improving dental occlusion. *Int J Orofacial Myology* 1997;23:35-46.
34. Daglio S, Schwitzer R, Wüthrich J. Orthodontic changes in oral dyskinesia and malocclusion under the influence of myofunctional therapy. *Int J Orofacial Myology* 1993;19:15-23.
35. Daglio S, Schwitzer R, Wüthrich J, Kallivroussis G. Treating orofacial dyskinesia with functional physiotherapy in the case of frontal open bite. *Int J Orofacial Myology* 1993;19:11-4.
36. Carvalho MP, Sato-Tsuji AM, Ferreira FAC, dos Santos JH, Scanavini JR, Julien MPR, et al. Evaluation of orofacial muscle dysfunction in orthodontics. *Int J Orofacial Myology* 1992;18:14-20.
37. Zimmerman JB. Orofacial myofunctional therapy for bilateral tongue posture and tongue thrust associated with open bite: a case report. *Int J Orofacial Myology* 1989;15:5-9.
38. Straub WJ. Malfunction of the tongue, part I. *Am J Orthod* 1960;46:404-24.
39. Straub WJ. Malfunction of the tongue, part II. *Am J Orthod* 1961;47:596-617.
40. Straub WJ. Malfunction of the tongue, art III. *Am J Orthod* 1962;48:486-503.
41. Weiss CE, van Houten JT. A remedial program for tongue-thrust. *Am J Orthod* 1972;62:499-506.
42. Pedrazzi ME. Treating the open bite. *J Gen Orthod* 1997;8:5-16.
43. Fujiki T, Takano-Yamamoto T, Noguchi H, Yamashiro T, Guan G, Tanimoto K. A cineradiographic study of deglutitive tongue movement and nasopharyngeal closure in patients with anterior open bite. *Angle Orthod* 2000;70:284-9.
44. Speidel T, Isaacson RJ, Worms FW. Tongue-thrust therapy and anterior dental open-bite. *Am J Orthod* 1972;62:287-94.
45. Gottlieb EL. Orthodontics vs myofunctional therapy. *J Clin Orthod* 1977;11:83-5.
46. Dahan JS, Lelong O. Effects of bite raising and occlusal awareness on tongue thrust in untreated children. *Am J Orthod Dentofacial Orthop* 2003;124:165-72.
47. Marasa F. Early mixed dentition treatment of a Class I open bite tendency malocclusion. *J Am Acad Gnathol Orthop* 1999;16:4-8.
48. Gugino CF, Dus I. Unlocking orthodontic malocclusions: interplay between form and function. *Semin Orthod* 1998;4:246-55.
49. Klocke A. Ask us. *Am J Orthod Dentofacial Orthop* 2003;123(3):13A.
50. Brandt S. JCO interviews Dr. William R. Proffit on the proper role of myofunctional therapy. *J Clin Orthod* 1977;11:101-15.
51. Sim JM. Twelve rules of orthodontic treatment during mixed dentition. *J Gen Orthod* 1998;9:22-7.
52. Ngan P, Fields HW. Open bite: a review of etiology and management. *Pediatr Dent* 1997;19:91-8.
53. Ferguson JW. The assessment and treatment of anterior open bite. *Dent Update* 1995;22:163-8.
54. Hanson ML, Mason RM. Orofacial myology: international perspectives. Springfield, Ill: Charles C. Thomas; 2003. p. 15-16.
55. Svensson P, Romaniello A, Arendt-Nielsen L, Sessle BJ. Plasticity in corticomotor control of the human tongue musculature induced by tongue-task training. *Exp Brain Res* 2003;152:42-51.
56. Robb SI, Sadowsky C, Schneider BJ, BeGole EA. Effectiveness and duration of orthodontic treatment in adults and adolescents. *Am J Orthod Dentofacial Orthop* 1998;114:383-6.
57. Beckwith FR, Ackerman RJ, Cobb CM, Tira DE. An evaluation of factors affecting duration of orthodontic treatment. *Am J Orthod Dentofacial Orthop* 1999;115:439-47.
58. Gottlieb EL, Cozzani M, de Harfin JF, Helmholt RD, Logan LR, Warren DW. JCO roundtable: stability of orthodontic treatment, part 2. *J Clin Orthod* 2006;40:83-94.
59. Efstratiadis SS. An American Board of Orthodontics case report. Treatment of an open bite malocclusion. *Am J Orthod Dentofacial Orthop* 1990;98:94-102.